



## PATIENT

Gemma Gonzalez

## SPECIES

Canine

## BREED

King Charles Cavalier

## SEX

FS

## AGE

8

## WEIGHT

24

## INTERPRETED BY

R. McKenzie Daniel,  
DVM, DABVP  
(Canine and Feline)

## IMAGING PERFORMED BY

Jenn

## HOSPITAL NAME

Rockaway Animal  
Hospital

## REFERRING VET

Dr Maniar

## INVOICE

23222

## DATE

12/15/2025

## PRESENTING CLINICAL SIGNS

Ate owners meds (Otezla)

Abnormal PE/Chem/CBC/UA Results: ALP 571 Lipase 709

## ULTRASONOGRAPHIC EXAMINATION OF THE ABDOMEN

### *Urinary System*

The urinary bladder, trigone, cystourethral junction, and visible pelvic urethra to a depth of 2 cm exhibited normal thickness and tone. Anechoic urine was present in the lumen with no evidence of urine/lumen sediment, mineral, or calculi. The ureteral papillae were normal. The ureters were not visible which is normal. No evidence of inflammatory or neoplastic changes was noted.

Normal size and margination were present in the kidneys. A normal 1:3 cortex / medulla ratio and normal corticomedullary definition were maintained. The echogenicity of the cortex was similar to or slightly less than normal liver parenchyma while the medulla echogenicity was hypoechoic to the cortex with no evidence of pelvic dilation. The left kidney measured 5.6 cm in length. The right kidney measured 5.6 cm in length.

The area of the aortic trifurcation was free of pathology.

### *Adrenal Glands*

The left adrenal gland was uniform in size and contour with a uniformly hypoechoic parenchyma. The left adrenal gland measured 0.6 cm width at the caudal pole. The right adrenal gland was uniform in size and contour with a uniformly hypoechoic parenchyma. The right adrenal gland measured 0.49 cm width at the caudal pole.

### *Spleen*

The spleen exhibited a finely textured and homogenous parenchyma which was hyperechoic to the liver and renal cortical parenchyma. The capsule was smooth and regular without apparent expansion. The splenic vasculature at the hilus was normal in volume with no evidence of congestion or thrombosis. Acute to chronic inflammatory, neoplastic, or benign parenchyma changes were not noted.

### *Liver/Gallbladder*

The liver presented enlarged in size. The parenchyma of the liver was subjectively normal in echogenicity compared to the spleen and renal cortices. The liver parenchyma was uniform with a mildly coarse echotexture. The capsule of the liver was symmetrically rounded to mildly swollen in margination. The hepatic and portal vasculature were normal in appearance without signs of congestion. The gallbladder was non-distended in size with primarily anechoic luminal content. The cystic and common bile ducts were normal.

### *Gastrointestinal*

The stomach presented intact wall layering with a normal wall layer ratio. The lumen of the stomach contained mild retained gastric fluid with mild lumen gas and no signs of obstruction or foreign material.



## PATIENT

Gemma Gonzalez

The small intestine presented intact wall layering with 1:3 muscularis/mucosa ratio. The lumen of the small intestine was empty with no signs of mechanical/metabolic ileus, obstruction or foreign material.

Normal visible colon wall layers were present with apparent formed feces in lumen.

## SPECIES

Canine

### *Pancreas*

The area of the pancreas was sonographically normal.

### *Free Abdomen*

No omental masses, overt lymphadenopathy or peritoneal effusion was present.

## BREED

King Charles Cavalier

## ULTRASONOGRAPHIC FINDINGS

### SEX

FS

### Primary

- Benign hepatopathy-sonographically suggestive of vacuolar hepatopathy criteria
- Normal gallbladder
- Possible mild hypomotile gastroduodenitis- no evidence of gastrointestinal obstructive pattern or foreign material
- Sonographically normal area of pancreas

### AGE

8

## INTERPRETATION OF THE FINDINGS & FURTHER RECOMMENDATIONS

### WEIGHT

24

Gastrointestinal support, empirical therapy for potential clinical signs associated with medication ingestion and supportive care for potential low-grade pancreatitis, which may present sonographically normal with clinical monitoring is recommended.

### INTERPRETED BY

R. McKenzie Daniel,  
DVM, DABVP  
(Canine and Feline)

Correlation with possible anticipated clinical signs associated with medication ingestion is recommended.

### IMAGING PERFORMED BY

Jenn

### HOSPITAL NAME

Rockaway Animal  
Hospital

### REFERRING VET

Dr Maniar

### INVOICE

23222

### DATE

12/15/2025



**PATIENT**

Gemma Gonzalez

**SPECIES**

Canine

**BREED**

King Charles Cavalier

**SEX**

FS

**AGE**

8

**WEIGHT**

24

**INTERPRETED BY**

R. McKenzie Daniel,  
DVM, DABVP  
(Canine and Feline)

**IMAGING PERFORMED BY**

Jenn

**HOSPITAL NAME**

Rockaway Animal  
Hospital

**REFERRING VET**

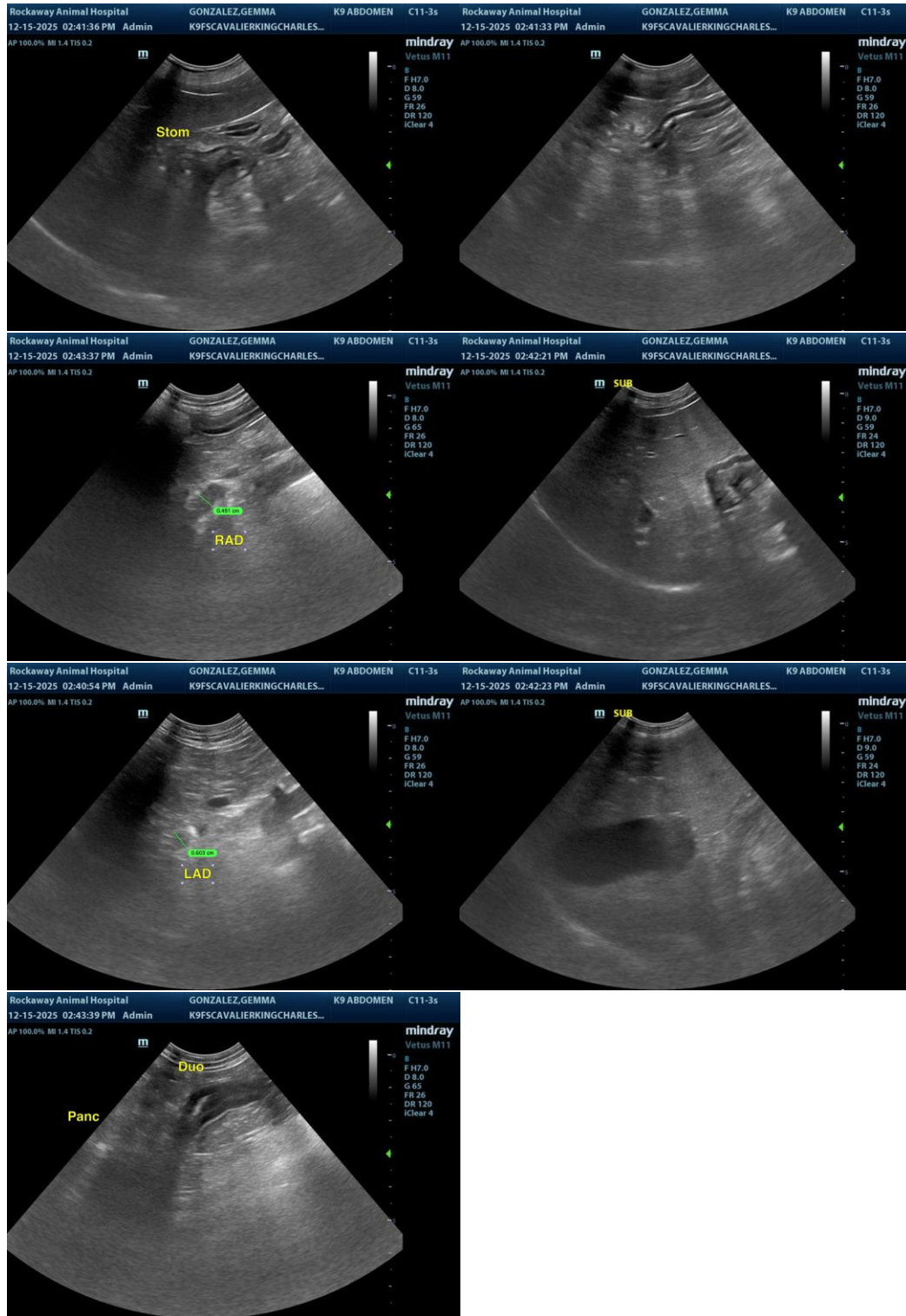
Dr Maniar

**INVOICE**

23222

**DATE**

12/15/2025



The information and recommendations provided are based on the images presented by the referring veterinarian/sonographer. No evaluation can be communicated regarding pathology that was not



## PATIENT

Gemma Gonzalez

visible in the image/video clips provided.

Thank you for this referral. If the clinical or image interpretation does not parallel your findings or if I can be of any further assistance, please contact me.

## SPECIES

Canine

R. McKenzie Daniel, DVM, DABVP (Canine/Feline Practice)  
[info@sonopath.com](mailto:info@sonopath.com)

## BREED

King Charles Cavalier

## SEX

FS

## AGE

8

## WEIGHT

24

## INTERPRETED BY

R. McKenzie Daniel,  
DVM, DABVP  
(Canine and Feline)

## IMAGING PERFORMED BY

Jenn

## HOSPITAL NAME

Rockaway Animal  
Hospital

## REFERRING VET

Dr Maniar

## INVOICE 23222

DATE  
12/15/2025